

⇒ Research Article



Effect of Vitamin E on Renal Scarring in Children With Acute Pyelonephritis: A Randomized Controlled Clinical Trial

Kambiz Ghasemi¹ , Maryam Esteghamati¹, Khatereh Arjeh²¹Department of Pediatric Nephrology, Clinical Research Development Center of Children's Hospital, Hormozgan University of Medical Sciences, Bandar Abbas, Iran²Department of Pediatrics, Faculty of Medicine, Hormozgan University of Medical Sciences, Bandar Abbas, Iran**Abstract**

Background: Urinary tract infection (UTI) is among the most common infections in children and acute pyelonephritis (APN) is the most important type of UTI. Late diagnosis and treatment of APN can result in severe complications. This study aimed to evaluate the effect of vitamin E on renal scars in children aged three months to 14 years.

Methods: This single-blinded randomized clinical trial (RCT) included all children aged three months to 14 years admitted to tBandar Abbas Children's Hospital, Bandar Abbas, Iran due to APN in 2017-2018. Patients with renal scars were alternately randomized into two groups. The control group included 41 patients who received 50-75 mg/kg/d intravenous ceftriaxone during hospital stay and the intervention group included 37 cases who received 20 U/kg/d vitamin E tablets in addition to the previous treatment for a total duration of 4 months. Dimercaptosuccinic acid (DMSA) scan was performed at baseline and at the end of 4 months.

Results: Out of a total of 78 patients, 34 (43.6%) were boys. Participants of both groups were comparable regarding age and gender. The median of decrease in photopenic areas was insignificantly higher in girls in the vitamin E group compared to girls in the control group (1.26 vs. 1.17, $P=0.459$). Regardless of gender, decrease in photopenic areas was insignificantly higher in patients aged 1-3 years in the vitamin E group compared to those in the control group (1.40 vs. 1.22, $P=0.451$).

Conclusion: Treatment with vitamin E for at least 4 months may reduce renal scarring in children aged 1-3 years and girls with APN.

Keywords: Vitamin E, Pyelonephritis, Children, Kidney scarring

***Correspondence to**

Kambiz Ghasemi,
Email: kambizghasemi@
yahoo.com



Received May 6, 2021, Accepted: June 13, 2021, Published Online: March 29, 2022

Background

Urinary tract infections (UTIs) are very common during childhood; it has been reported that by the age of 16 years, up to 11.3% of girls and 3.6% of boys have UTI (1). Besides, UTI is among the leading causes of pediatric hospital admission. Most often, UTI primarily presents as cystitis and only the lower urinary tract is involved. If left untreated, bacteria causing cystitis can ascend, and by infecting the kidneys, progress into pyelonephritis (2,3). Acute pyelonephritis (APN) results in end-stage renal failure in 8-20% of children and young adults (4). At early stages, APN presents with nonspecific symptoms; however, specific signs may occur 1-3 days afterwards, and delayed diagnosis and treatment can result in irreversible renal scar formation (5). It has been shown that 5-15% of the first febrile UTI in children could lead to renal scarring (6).

Oxidative stress is believed to play a significant role in the pathogenesis of infections. Pyelonephritis is likely to be mediated, at least in part, by oxidant injury (7), and this

has been established in some studies (8-10). In a study by Pavlova et al, pyelonephritis caused a significant increase in the blood and urine concentrations of oxidative stress biomarkers. These findings suggest antioxidant therapy, given as adjunct to antibiotics, as an option for children with pyelonephritis (11, 12).

The use of vitamins as antioxidants against free oxygen radicals seems to be a promising strategy in the prevention of renal scarring in APN. This notion has been supported by some animal studies (9, 13, 14); however, the effect of vitamin therapy on renal scarring in humans has been controversial.

Vitamin E is an antioxidant and plays a significant role in the cell antioxidant defense system; furthermore, it has many other biological functions, namely gene regulation, enzymatic activity, and inhibition of platelet aggregation (15-17). Vitamin E is also said to be effective against nephropathy, with acute kidney injury as one of its subtypes (18). Moreover, vitamin E seems to have a significant effect on subsiding the signs and symptoms of

UTI (19).

Based on the importance of APN, its resultant renal scarring, and future complications in children, and due to the possible role of vitamin E as an antioxidant in the protection of cells against oxidative stress caused by infections, the current study was designed.

Objectives

We aimed to evaluate the effect of vitamin E on renal scarring in children with APN.

Material and Methods

Participants

In this single-blinded randomized controlled trial (RCT), all children aged three months to 14 years admitted to Bandar Abbas Children’s Hospital, Bandar Abbas, Iran due to APN in 2017-2018 were consecutively enrolled. Diagnosis of APN was confirmed by a pediatrician based on the results of urine culture and clinical manifestations, such as fever and abdominal pain. Exclusion criteria were vesicoureteral reflux, dysplastic or hypoplastic kidneys, and neurogenic bladder. Sample size was calculated as at least 30 in each group based on $\alpha = 0.05$ and $\beta = 0.2$.

Study Design

The Ethics Committee of Hormozgan University of Medical Sciences approved the study complied with the Declaration of Helsinki. Written informed consent was

obtained from parents/guardians of all participants. Figure 1 shows the total number of patients eligible to enter the study and those who were included in the final analysis. Dimercaptosuccinic acid (DMSA) scan (using Siemens E.Cam® single-head scanner) was performed at baseline at Bandar Abbas Children’s Hospital. According to the inclusion criteria, a total of 78 patients with renal scars were alternately randomized into two groups using a randomization table generated by the Random Allocation software. The control group included 41 patients who received 50-75 mg/kg/d intravenous ceftriaxone during hospital stay and the intervention group included 37 cases who received 20 U/kg/day vitamin E tablets in addition to the previous treatment for a total duration of four months. Another DMSA scan was performed at the end of four months at Bandar Abbas Children’s Hospital. All DMSA evaluations were done by an expert pediatric nephrologist who was blinded to the grouping of patients. Photopenic areas on the DMSA scan were regarded as involved parenchymal areas or renal scars. Demographic features of the participants, including age and gender were also recorded. Participants were divided into three groups based on age: 3 months-1 year, 1-3 years, and >3 years. Erythrocyte sedimentation rate (ESR) and C-reactive protein (CRP) were measured at baseline for all participants.

Data Analysis

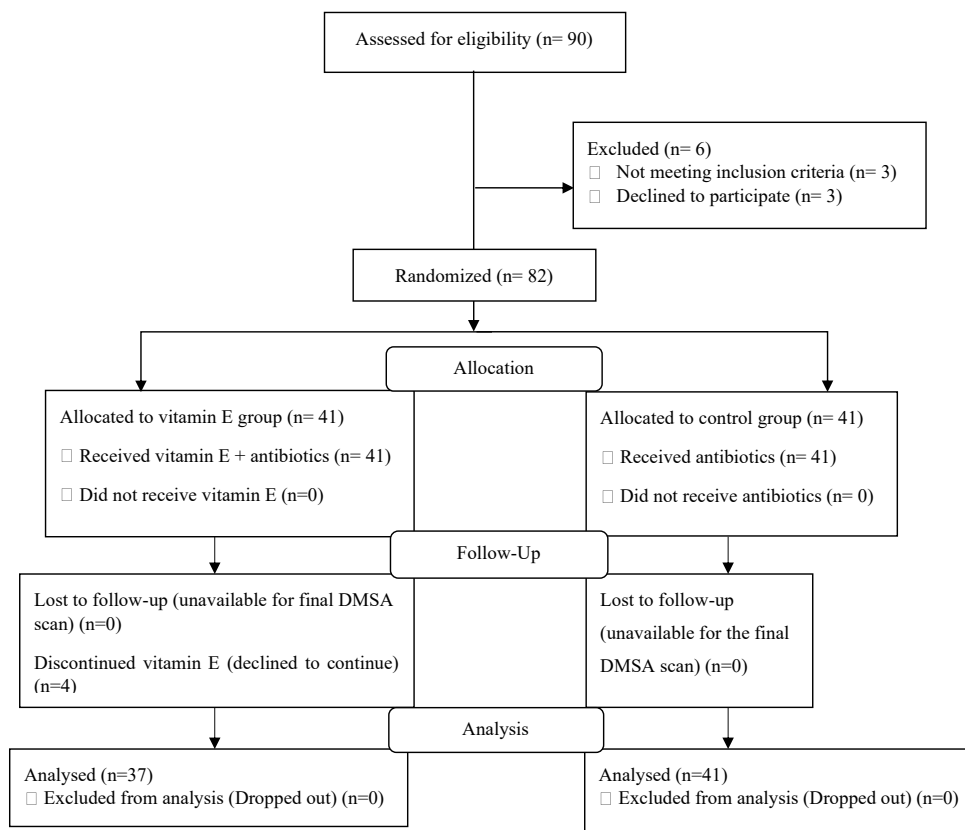


Figure 1. Study Flowchart (CONSORT Format).

The Statistical Package for the Social Sciences (SPSS) software (version 25.0, Armonk, NY: IBM Corp. USA) was used for data analysis. Mean, median, standard deviation, frequency, and percentages were used to describe the results. *P* values of equal to or less than 0.05 were regarded as statistically significant. All quantitative variables were non-normally distributed based on the Kolmogorov-Smirnov normality test. Thus, the nonparametric Mann-Whitney test was used to compare them between groups. The chi-square and the Fisher's exact tests used to compare qualitative variables between groups.

Results

The mean age of the participants was 46.97 ± 34.51 months, and 34 (43.6%) patients were male. In terms of age and gender, the participants were homogeneously distributed in the study groups (vitamin E and control) (Table 1). Baseline medians of ESR and CRP did not differ significantly between cases and controls (40 vs. 39.17 mm/h, $P=0.549$; 55.31 vs. 55.53 mg/L, $P=0.461$, respectively).

The number of photopenic areas in the baseline DMSA scan was not significantly different between groups (Table 2). In addition, there was no significant difference between groups regarding the reduced number of photopenic areas in the DMSA scan at the end of four months of treatment (Table 3).

The median of decrease in photopenic areas was insignificantly higher in girls in the vitamin E group compared to girls in the control group (1.26 vs. 1.17, $P=0.459$). Furthermore, regardless of gender, the decrease in photopenic areas was insignificantly higher in patients aged 1-3 years in the vitamin E group compared to those in the control group (1.40 vs 1.22, $P=0.451$) (Table 4).

Discussion

Based on to our results, although vitamin E caused no significant reduction in renal scarring, this vitamin seems to slightly reduce pyelonephritic scars in girls and children aged 1-3 years. Yousefichaijan et al investigated the effect of vitamin E supplementation in combination

with antibiotics for the treatment of APN in girls (19). In this double-blinded RCT, 152 girls aged 5-12 years with a first APN were evaluated. Girls were randomized to either receive a 14-day treatment with only antibiotics or a 14-day treatment with vitamin E supplements plus antibiotics. The intervention groups had significantly lower mean frequency of signs and symptoms, including fever, urinary frequency, urgency, and incontinence in the follow-up period compared to the control group. Neither

Table 1. Distribution of Demographic Features of Participants

Variable	Groups		Total No. (%)	<i>P</i> Value*
	Vitamin E No. (%)	Control No. (%)		
Gender	Male	17 (50)	17 (50)	0.690
	Female	20 (45.5)	24 (54.5)	
Age	3 months-1 year	9 (50)	9 (50)	0.907
	1-3 years	10 (50)	10 (50)	
	>3 years	18 (45)	22 (55)	
Total	37 (47.4)	41 (52.6)	78 (100)	

*Analyzed by chi-square test

Table 2. Baseline DMSA Results

Variable		Photopenic Areas N (%)				<i>P</i> Value*
		1	2	3	4	
Study Groups	Vitamin E	25 (37.6)	6 (16.2)	5 (13.5)	1 (2.7)	0.655
	Control	31 (75.6)	7 (17.1)	3 (7.3)	0 (0)	
Total		56 (71.8)	13 (16.7)	8 (10.3)	1 (1.3)	

*Analyzed by the chi-square test

Table 3. DMSA Results at the End of Treatment (After 4 Months)

Variable		Reduced Number of Photopenic Areas N (%)				<i>P</i> Value*
		0	1	2	3	
Study Groups	Vitamin E	0 (0)	29 (76.4)	7 (18.9)	1 (2.7)	1.000
	Control	1 (2.4)	31 (75.6)	8 (19.5)	1 (2.4)	
Total		1 (1.3)	60 (76.9)	15 (19.2)	2 (2.6)	

*Analyzed by the Fisher's exact test

Abbreviations: N, number

Table 4. Comparison of Reduction in Photopenic Areas in General Based on Gender and Age

Variable		Reduction in Photopenic Areas				<i>P</i> Value*
		Vitamin E		Control		
		Median	Mean \pm SD	Median	Mean \pm SD	
Gender	Male	1.18	1.18 \pm 0.39	1.27	1.29 \pm 0.69	0.708
	Female	1.26	1.30 \pm 0.57	1.17	1.17 \pm 0.38	
Age	3 months-1 year	1.22	1.22 \pm 0.44	1.22	1.22 \pm 0.44	1.000
	1-3 years	1.40	1.40 \pm 0.52	1.22	1.30 \pm 0.68	
	>3 years	1.12	1.17 \pm 0.51	1.19	1.18 \pm 0.50	
Total		1	1.24 \pm 0.50	1	1.22 \pm 0.53	0.865

Abbreviations: SD, standard deviation.

*Analyzed by Mann Whitney test.

the results of urine culture 3-4 days after the initiation of the treatment nor 7-10 days after its termination were significantly different between the groups. No significant difference was found between the groups regarding the results of DMSA scan 4-6 months after the initiation of the treatment (19). Their results were consistent with our findings regarding the insignificant difference in DMSA scans after treatment; however, this study was only performed on girls and the study design was quite different from ours.

In an RCT by Sobouti et al on 61 children aged 1 month-10 years, in two DMSA scans done at least six months apart, exacerbation of renal lesions was observed in 42.5%, 0, and 23.3% of the control, vitamin E, and vitamin A patients, respectively. Thus, vitamin A or E supplements were effective in reducing renal scarring secondary to APN compared to no vitamin supplementation, and vitamin E was more effective than vitamin A in this regard (14). Since the role of vitamin A in preventing renal scarring after APN in children has been established (5, 12), and based on the results of the current study, the role of vitamin E in the prevention of renal scarring in children can be promising.

The effect of vitamin E has also been evaluated in animal models. In a study on rats, the animals were divided into three groups. In addition to five consecutive days of intraperitoneal ceftriaxone injection in the first group, beginning on the third day after inoculation, the rats in the second group were also given allopurinol; meanwhile, in the third group, vitamin E was started at fever onset. Both kidneys of all rats were excised six weeks after the treatment and pathologic scores of inflammation and fibrosis in the first group (controls) were higher than in the vitamin E and allopurinol groups. Apoptosis index was also decreased in the second and third groups compared to controls (13).

Furthermore, another study on APN in rats investigated the effect of co-supplementation of vitamins E and C on renal scarring. No or mild renal scarring was observed in vitamin E and C groups compared to the control group; however, the difference between vitamin E and C groups was not significantly different. This study showed that administration of antioxidants can protect scarring due to pyelonephritis with or without administration of antibiotics (9).

The main strength of the current study is that it is among the few studies evaluating the effect of human models, as opposed to previous studies on animals. Moreover, the homogeneity of cases and controls in terms of demographic information, as well as baseline DMSA scans, facilitated the exclusive assessment of the effect of vitamin E.

The current study had no prominent limitations. However, a larger sample size would have contributed to the generalizability of the results. In general, further

studies with larger human samples are required to determine the effect of vitamin E on renal scarring. More RCTs are required to compare the effects of vitamins E, A, and C on renal scarring.

Conclusion

Treatment with vitamin E for at least four months can slightly reduce renal scarring in children 1-3 years old and girls with APN. Supplementation of vitamin E is recommended in girls and this age group.

Acknowledgements

We sincerely appreciate the dedicated efforts of the investigators, the coordinators, the volunteer patients and their parents, and the Pediatric Hospital of Bandar Abbas, Iran.

Conflict of Interests

No conflict of interests has been declared by the authors of this article.

Ethical Approval

This study was approved by the Ethics Committee of Hormozgan University of Medical Sciences under the ethics code: IR.HUMS.REC.1397.061.

Funding/Support

The study received no funds.

References

- Bandari B, Sindgikar SP, Kumar SS, Vijaya MS, Shankar R. Renal scarring following urinary tract infections in children. *Sudan J Paediatr*. 2019;19(1):25-30. doi: [10.24911/sjp.106-1554791193](https://doi.org/10.24911/sjp.106-1554791193).
- Canadian Institute for Health Information (CIHI). Treatment of End-Stage Organ Failure in Canada, 1999 to 2008—CORR 2010 Annual Report. Ottawa: CIHI; 2010.
- Dharmidharka VR, Fiorina P, Harmon WE. Kidney transplantation in children. *N Engl J Med*. 2014;371(6):549-58. doi: [10.1056/NEJMra1314376](https://doi.org/10.1056/NEJMra1314376).
- Pleniceanu O, Twig G, Tzur D, Sherman G, Afek A, Erlich T, et al. Acute pyelonephritis in children and the risk of end-stage kidney disease. *J Nephrol*. 2021;34(5):1757-65. doi: [10.1007/s40620-020-00841-x](https://doi.org/10.1007/s40620-020-00841-x).
- Ayazi P, Moshiri SA, Mahyar A, Moradi M. The effect of vitamin A on renal damage following acute pyelonephritis in children. *Eur J Pediatr*. 2011;170(3):347-50. doi: [10.1007/s00431-010-1297-1](https://doi.org/10.1007/s00431-010-1297-1).
- Shaikh N, Ewing AL, Bhatnagar S, Hoberman A. Risk of renal scarring in children with a first urinary tract infection: a systematic review. *Pediatrics*. 2010;126(6):1084-91. doi: [10.1542/peds.2010-0685](https://doi.org/10.1542/peds.2010-0685).
- Allameh Z, Salamzadeh J. Use of antioxidants in urinary tract infection. *J Res Pharm Pract*. 2016;5(2):79-85. doi: [10.4103/2279-042x.179567](https://doi.org/10.4103/2279-042x.179567).
- Bychkovskikh VA, Dolgushin II, Korobeinikova ÉN. [The comparative study of indicators of immunity and state of pro-and antioxidant systems in patients with chronic pyelonephritis of single kidney in active and latent stages of disease]. *Klin Lab Diagn*. 2012(5):43-6.
- Emamghorashi F, Owji SM, Motamedifar M. Evaluation of effectiveness of vitamins C and E on prevention of renal scar due to pyelonephritis in rat. *Adv Urol*. 2011;2011:489496. doi: [10.1155/2011/489496](https://doi.org/10.1155/2011/489496).
- Mittal R, Sharma S, Chhibber S, Harjai K. Contribution of

- free radicals to *Pseudomonas aeruginosa* induced acute pyelonephritis. *Microb Pathog.* 2008;45(5-6):323-30. doi: [10.1016/j.micpath.2008.08.003](https://doi.org/10.1016/j.micpath.2008.08.003).
11. Pavlova EL, Lilova MI, Savov VM. Oxidative stress in children with kidney disease. *Pediatr Nephrol.* 2005;20(11):1599-604. doi: [10.1007/s00467-005-1990-x](https://doi.org/10.1007/s00467-005-1990-x).
 12. Nevés T. Can postpyelonephritic renal scarring be prevented? *Pediatr Nephrol.* 2013;28(2):187-90. doi: [10.1007/s00467-012-2334-2](https://doi.org/10.1007/s00467-012-2334-2).
 13. Sadeghi Z, Kajbafzadeh AM, Tajik P, Monajemzadeh M, Payabvash S, Elmi A. Vitamin E administration at the onset of fever prevents renal scarring in acute pyelonephritis. *Pediatr Nephrol.* 2008;23(9):1503-10. doi: [10.1007/s00467-008-0853-7](https://doi.org/10.1007/s00467-008-0853-7).
 14. Sobouti B, Hooman N, Movahed M. The effect of vitamin E or vitamin A on the prevention of renal scarring in children with acute pyelonephritis. *Pediatr Nephrol.* 2013;28(2):277-83. doi: [10.1007/s00467-012-2308-4](https://doi.org/10.1007/s00467-012-2308-4).
 15. Atkinson J, Epanand RF, Epanand RM. Tocopherols and tocotrienols in membranes: a critical review. *Free Radic Biol Med.* 2008;44(5):739-64. doi: [10.1016/j.freeradbiomed.2007.11.010](https://doi.org/10.1016/j.freeradbiomed.2007.11.010).
 16. Rizvi S, Raza ST, Ahmed F, Ahmad A, Abbas S, Mahdi F. The role of vitamin e in human health and some diseases. *Sultan Qaboos Univ Med J.* 2014;14(2):e157-65.
 17. Schneider C. Chemistry and biology of vitamin E. *Mol Nutr Food Res.* 2005;49(1):7-30. doi: [10.1002/mnfr.200400049](https://doi.org/10.1002/mnfr.200400049).
 18. Kongkham S, Sriwong S, Tasanarong A. Protective effect of alpha tocopherol on contrast-induced nephropathy in rats. *Nefrologia.* 2013;33(1):116-23. doi: [10.3265/Nefrologia.pre2012.Nov.11736](https://doi.org/10.3265/Nefrologia.pre2012.Nov.11736).
 19. Yousefichaijan P, Kahbazi M, Rasti S, Rafeie M, Sharafkhan M. Vitamin E as adjuvant treatment for urinary tract infection in girls with acute pyelonephritis. *Iran J Kidney Dis.* 2015;9(2):97-104.
 20. Emamghorashi F, Owji SM, Motamedifar M. Evaluation of effectiveness of vitamins C and E on prevention of renal scar due to pyelonephritis in rat. *Adv Urol.* 2011;2011:489496. doi: [10.1155/2011/489496](https://doi.org/10.1155/2011/489496).